

Color Doppler ultrasound flow patterns in hepatic vasculature

Poster No.: C-2537
Congress: ECR 2013
Type: Educational Exhibit
Authors: S. K. Chamarthi, W. Bennett, S. Barker; Columbus, OH/US
Keywords: Liver, Vascular, Ultrasound-Colour Doppler, Ultrasound-Spectral Doppler, Education, Cirrhosis
DOI: 10.1594/ecr2013/C-2537

Any information contained in this pdf file is automatically generated from digital material submitted to EPOS by third parties in the form of scientific presentations. References to any names, marks, products, or services of third parties or hypertext links to third-party sites or information are provided solely as a convenience to you and do not in any way constitute or imply ECR's endorsement, sponsorship or recommendation of the third party, information, product or service. ECR is not responsible for the content of these pages and does not make any representations regarding the content or accuracy of material in this file.

As per copyright regulations, any unauthorised use of the material or parts thereof as well as commercial reproduction or multiple distribution by any traditional or electronically based reproduction/publication method is strictly prohibited.

You agree to defend, indemnify, and hold ECR harmless from and against any and all claims, damages, costs, and expenses, including attorneys' fees, arising from or related to your use of these pages.

Please note: Links to movies, ppt slideshows and any other multimedia files are not available in the pdf version of presentations.

www.myESR.org

Learning objectives

Doppler sonography of the liver plays an important role in the evaluation of liver vasculature. It is usually the initial modality used for evaluating flow in the native liver vessels, transjugular intrahepatic portosystemic shunts (TIPS) and vascular complications in the liver transplants. This is easily available, noninvasive, ionizing radiation-free, portable technique and provides anatomic and hemodynamic information.

The objectives of this exhibit are to illustrate

- Characteristic appearances of normal waveforms
- Abnormal Doppler waveforms
- Normal and abnormal TIPS flow pattern
- A few posttransplant vascular complications

Background

Doppler sonography is the initial investigation of choice for evaluating hepatic vasculature. Proper understanding of the normal waveforms and physiology of their generation is important in the interpretation of hepatic Doppler studies. Limited number of abnormal patterns are seen with majority of liver diseases. An organized approach will help improve competency in interpreting these studies.

Hepatic artery:

Normal waveform

A pulsatile waveform is seen in a normal hepatic artery(Fig 1). Normal artery shows forward flow throughout the cardiac cycle. The arterial flow will be above baseline in the main hepatic artery if it is in correct orientation. Hepatic artery demonstrates low-resistance flow pattern as the liver requires blood flow throughout the cardiac cycle. Normal resistivity index ranges from 0.55 to 0.7.

Abnormal waveforms

Liver disease may result in either elevated (RI >0.7) or decreased (RI <0.55) resistance.

High resistance flow (Fig 2) can be seen in following conditions:

- Postprandial state
- Advanced age
- Diffuse peripheral arteriolar compression. This can be in chronic hepatocellular diseases such as cirrhosis, hepatic venous congestion, cold ischemia, and transplant rejection.

Low resistance flow (Fig 3) can be seen in following conditions:

- Upstream arterial narrowing (transplant hepatic artery stenosis or thrombosis).
- Atherosclerosis involving hepatic or celiac artery.
- Arcuate ligament syndrome
- Peripheral vascular shunts. These can be posttraumatic or iatrogenic arteriovenous fistulas, arteriovenous or arterioportal shunts in cirrhotics, Osler-Weber-Rendu syndrome with arteriovenous fistulas.

Hepatic arterial resistance in cirrhosis can be variable. It can be normal, increased or decreased due to the combined effect of several factors. Factors such as inflammatory edema, arterial compression by regenerative nodules or by stiff noncompliant fibrotic liver parenchyma may result in increased resistance. Factors such as compensatory small artery proliferation, increased numbers of arteriolar beds and arteriovenous shunting may result in decreased resistance. It has been shown that hepatic arterial RI is not useful in the diagnosis of cirrhosis or predicting its severity.

Portal vein

Normal waveform:

The normal portal venous waveform shows slight undulation and always remains above the baseline (hepatopetal) if it is in correct orientation (Fig 4). The peak portal velocity (V_1) corresponds to systole, and the trough velocity (V_2) corresponds to end diastole. The primary factor influencing the portal venous pressure variation is atrial contraction. Atrial contraction is the last phase during diastole and transmits back pressure to the portal circulation through hepatic veins and sinusoids. Forward portal venous flow will be decreased during atrial contraction (trough). The degree of undulation is highly variable and can be quantified with pulsatility index (PI). The PI is calculated as V_2/V_1 . Normal phasicity of portal vein results in a PI of higher than 0.5. Normal flow velocity in portal vein is between 16-40 cm/sec.

Abnormal waveforms:

Abnormal portal venous flow results in one of the following flow patterns.

Increased pulsatility (Fig 5): A large difference between flow velocity at peak systole and at end diastole results in increased pulsatility. Any pathology that abnormally transmits pressure to the sinusoids will result in a pulsatile portal venous waveform. Tricuspid regurgitation and right-sided CHF transmit pressure through the hepatic veins and increase pulsatility. Arterial abnormalities that can increase pulsatility include arteriovenous shunting (cirrhosis) or fistulas. Tricuspid regurgitation and right-sided CHF can be differentiated from cirrhosis by simultaneous assessment of hepatic venous waveforms. Cardiac conditions are associated with dilated hepatic veins at gray-scale US. Cirrhosis manifests as compressed hepatic veins.

Sluggish flow (Fig 6): Abnormally slow flow (peak systolic velocity less than 16 cm/sec) occurs with increased portal pressure that limits forward velocity. This is diagnostic for portal hypertension. Most common cause of portal hypertension is cirrhosis. Other causes include portal vein thrombosis, right-sided heart failure, tricuspid regurgitation, and Budd-Chiari syndrome.

Flow reversal (Fig 7): Hepatofugal flow occurs when back pressure exceeds forward pressure, with subsequent flow reversal. This results in a waveform that is below the baseline. This finding is diagnostic for portal hypertension.

Absent flow: This can be seen with complete stagnation of flow that can be seen in portal hypertension or occlusive disease caused by bland or malignant thrombosis. Partial flow may be seen due to nonocclusive bland thrombus or tumor vascularity in malignant thrombus.

Hepatic veins

Normal waveform (Fig 8)

"a" wave: Corresponds to atrial contraction, which is the last phase in diastole. It is an upward-pointing wave which is above the baseline. The *a* wave is wider and taller than the *v* wave. The *a* wave remains wider than the *v* wave in pathological conditions. In severe tricuspid regurgitation, the *S* wave becomes retrograde and merges with the *a* and *v* waves to form a single large retrograde *a-S-v* complex.

"S" wave: Results from decreasing right atrial pressure as the atrioventricular septum descends toward the cardiac apex during early to midsystole. It is the largest downward-pointing wave in the cycle and represents antegrade hepatic venous flow. The lowest point of S wave occurs in midsystole. The wave rises again as pressure in the right atrium increases due to continued systemic venous return.

"v" wave: Corresponds to atrial overfilling. It results from increasing right atrial pressure due to continued systemic venous return against closed tricuspid valve. This occurs towards the end of systole. The peak of the wave indicates opening of the tricuspid valve and transition from systole to diastole. The peak of the v wave varies from above to below the baseline in normal states.

"D" wave: Results from decreasing right atrial pressure due to rapid right ventricular filling which is the first phase in cardiac diastole. The D wave also represents antegrade hepatic venous flow and is smaller than downward-pointing S wave in physiological state. The maximal antegrade diastolic velocity marks the lowest point. The subsequent rise in the waveform is due to increase in right atrial pressure from increasing right ventricular blood volume.

Evaluation of the hepatic vein spectral Doppler tracing involves assessment of four parameters.

- Direction of flow
- Regularity of flow pattern
- Phasicity
- Relationship of magnitude between the S and D waves

Flow direction: Absent or monophasic flow in the retrograde direction is seen with hepatic vein obstruction or IVC obstruction, such as in Budd-Chiari syndrome (Fig 9). No flow will be seen at the level of clot/obstruction. Interrogation of the vessel between the periphery of the liver and the clot will show complete flow reversal with monophasic waveform.

Regularity of flow pattern: Irregular flow can be seen with arrhythmias, turbulent blood flow, or degradation of the waveform which can be due to patient or technical factors (Fig 10). A degraded waveform is usually seen in sedated patients, patients receiving mechanical ventilation, and patients who have respiratory difficulties and cannot cooperate with breathing instructions.

Phasicity: Dampened monophasic flow is seen in diffuse liver diseases such as steatosis, cirrhosis, or diffuse hepatic metastatic disease (Fig 11). Hepatic vein stenosis is also associated with monophasic waveforms. Physiologic factors such as high intraabdominal

pressure due to Valsalva maneuver or suspending respiration in end expiration can also result in monophasic waveform.

Relationship of magnitude between the *S* and *D* waves: The *S* wave is larger than or equal to the *D* wave in physiological state. In Tricuspid regurgitation, there will be reversal of this relationship. In severe cases, there will be complete reversal of *S* wave which will be seen above the baseline. The *a* wave, *S* wave and *v* wave may form a complex above the baseline resulting in biphasic waveforms (fig 12). In right heart failure, the *S* wave will be smaller compared to *D* wave, however reversal above the baseline does not occur.

TIPS (transjugular intrahepatic portosystemic shunts)

TIPS are most commonly used for the treatment of severe portal hypertension with refractory variceal bleeding or ascites. The cephalic end of the shunt is most commonly located immediate to the connection of the right hepatic vein with the IVC. The caudal end is located in the right portal vein. The normal flow velocity is between 90-190 cm/sec (Fig 13). Shunt malfunction can be due to luminal narrowing or occlusion caused by intimal hyperplasia or in situ thrombosis (Fig 14).

Signs of shunt malfunction include:

- An abnormally high (>190 cm/sec) or abnormally low (<90 cm/sec) velocity within the shunt (Fig 15 &16).
- Abnormal change in velocity (increase or decrease >50 cm/sec) compared with the prior examination.
- Intrahepatic portal venous flow that was hepatofugal on the prior examination and has changed to hepatopetal flow.
- Low velocity (<30 cm/sec) in the main portal vein.
- Development or recurrence of collateral vessels such as a recanalized umbilical vein.

Posttransplant complications

Hepatic artery

- Thrombosis: Absent arterial flow in the thrombus with tardus Parvus waveforms in the intrahepatic arteries downstream from stenosis. In parvus tardus waveform, peak of the waveform is too late (tardus) and too low (parvus). This occurs with upstream stenosis or thrombosis.
- Stenosis: Accelerated velocity greater than 2-3 m/sec at the site of narrowing with Parvus tardus waveforms in the intrahepatic arteries downstream from stenosis(Fig 3).

- Pseudoaneurysms: Disorganized arterial flow pattern with possible intrahepatic arterial tardus-parvus waveforms.

Portal vein

- Thrombosis: An echogenic thrombus may be seen with no Doppler flow.
- Stenosis: Luminal narrowing with focal color aliasing and more than a three- to fourfold increase in velocity at the stenosis relative to that at the prestenotic segment (Fig 17).

IVC and associated hepatic vein

- Thrombosis: An echogenic thrombus may be seen with no Doppler signal.
- Stenosis: Three- to fourfold increase in velocity at the stenotic area compared to prestenotic segment.

Images for this section:

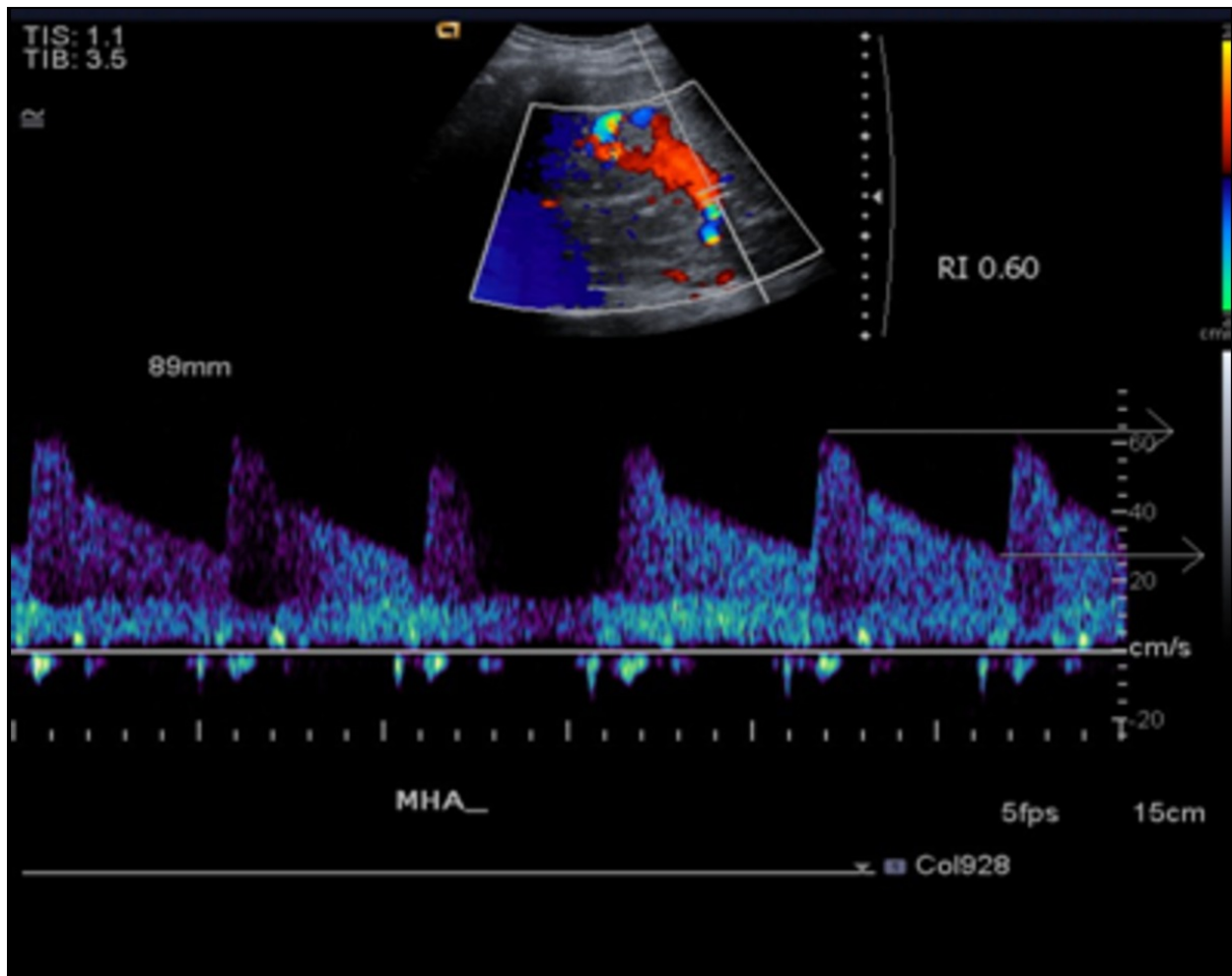


Fig. 1: Normal low resistance flow pattern in hepatic artery. Flow is seen above the baseline throughout the cardiac cycle. RI is 0.6.

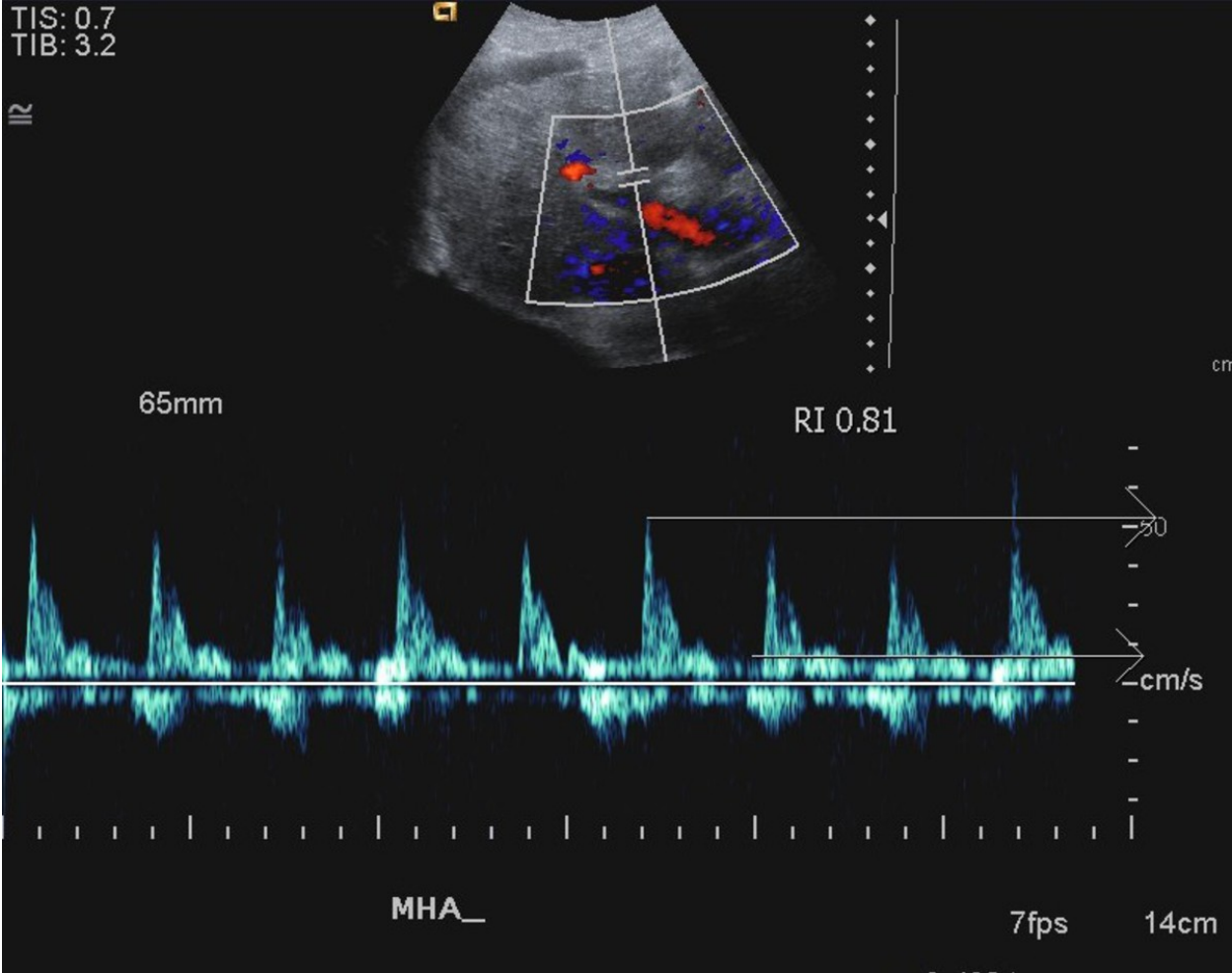


Fig. 2: High resistance flow in the hepatic artery seen in cirrhotic liver. RI is 0.81.

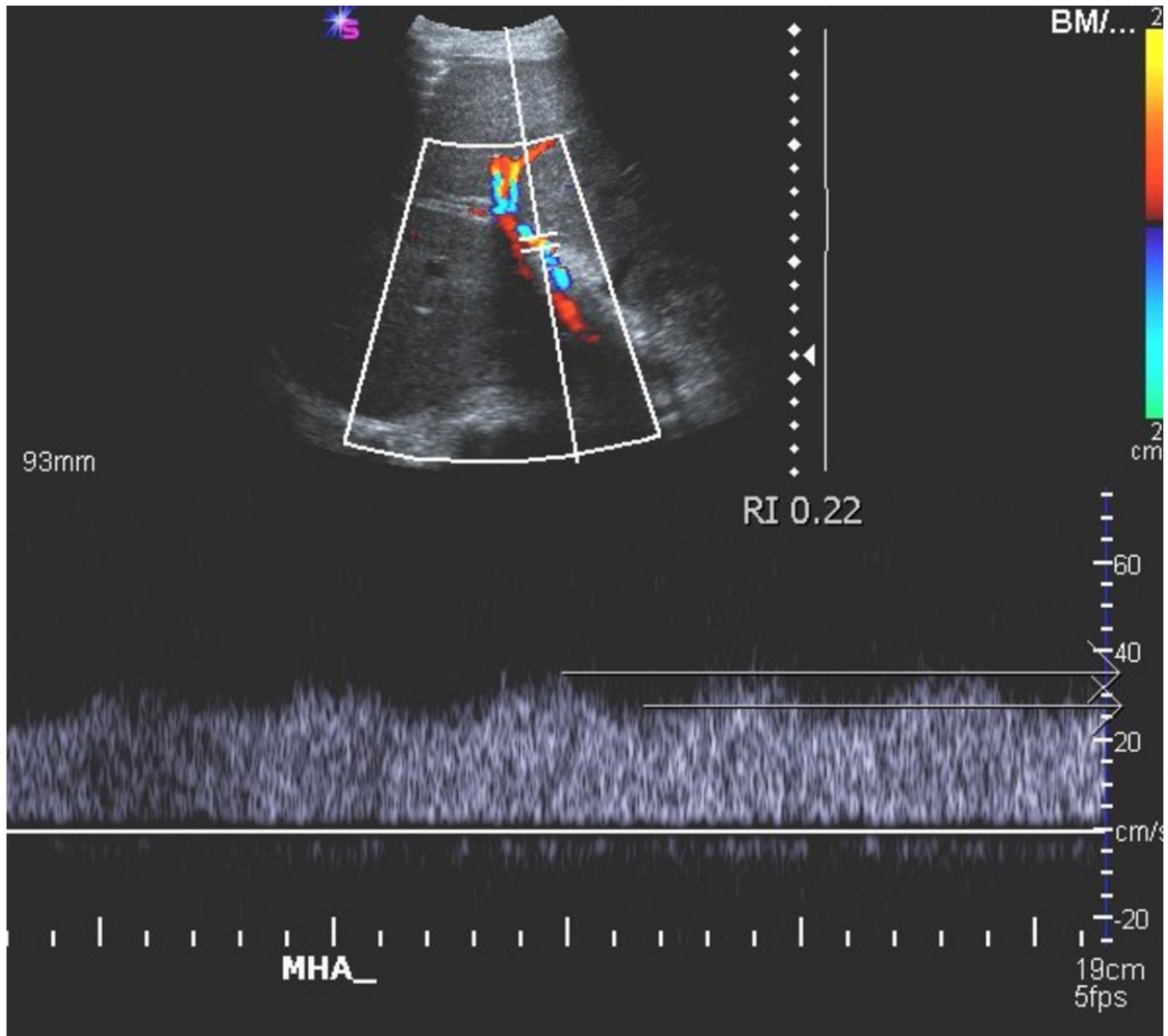


Fig. 3: Low resistance flow with a RI of 0.22 in the hepatic artery status post liver transplant due to stenosis in the hepatic artery at the anastomosis. Parvus tardus waveform noted with a prolonged acceleration time and decreased resistive index.

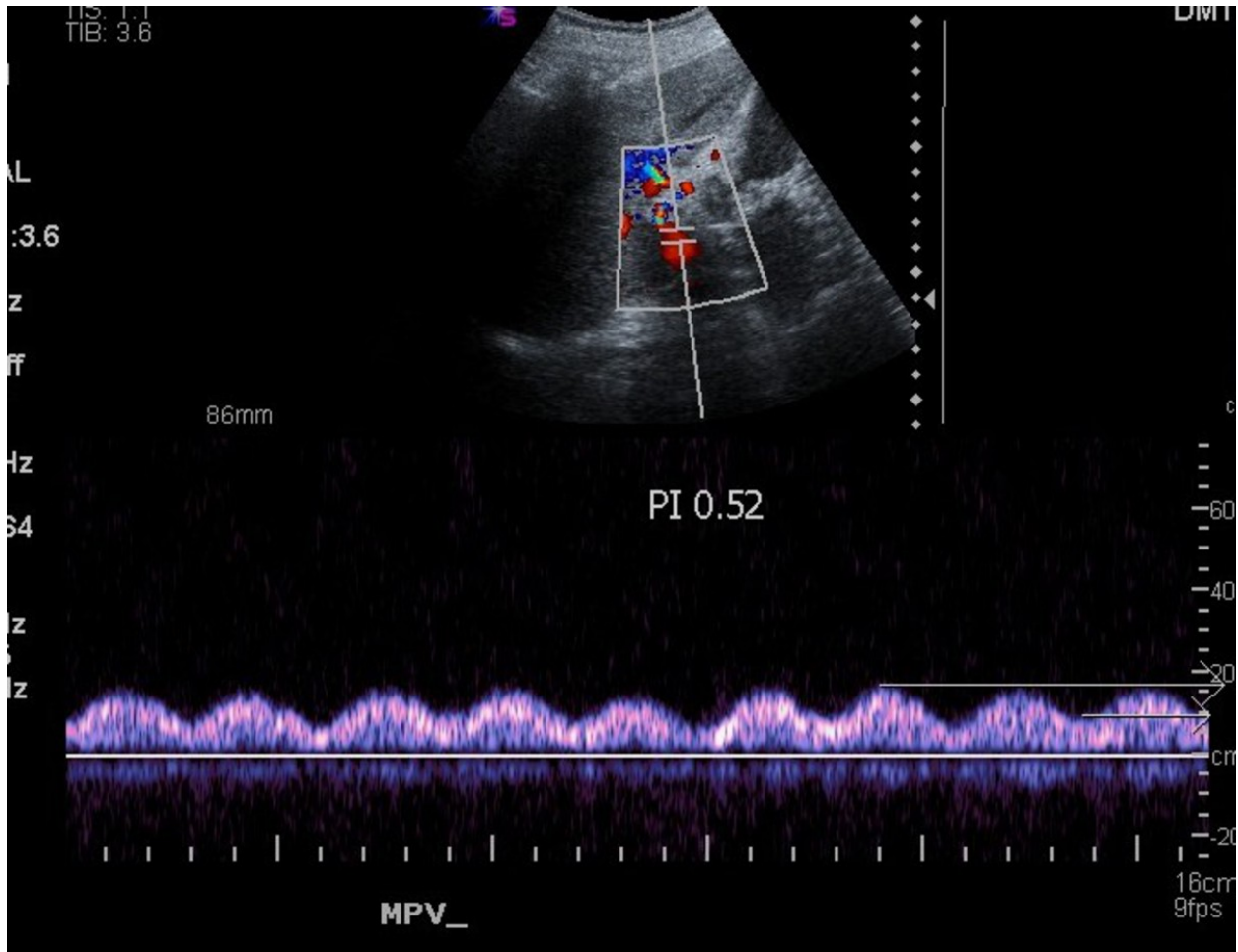


Fig. 4: Normal hepatopetal portal venous waveform with mild undulation. PI is 0.52.

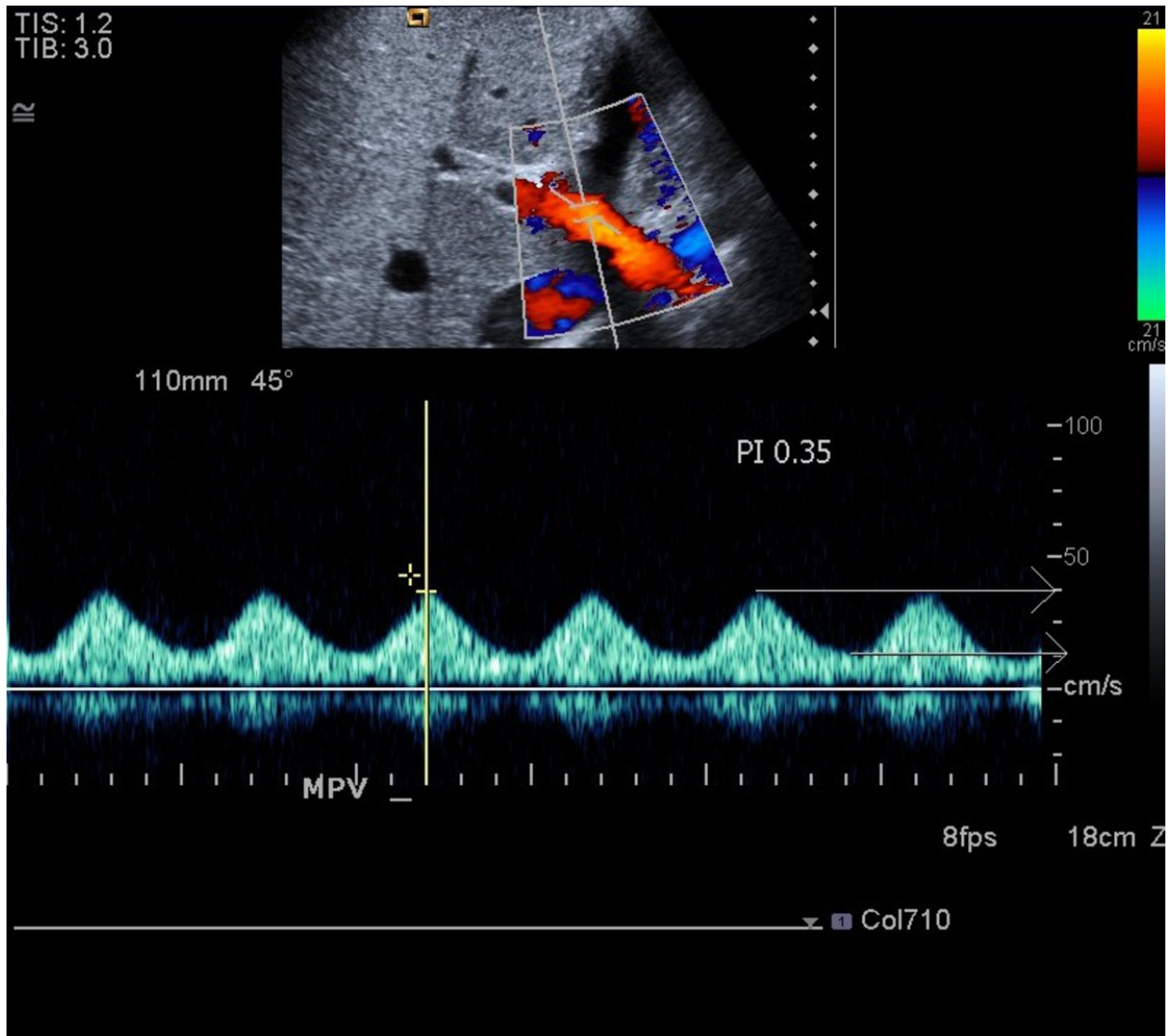


Fig. 5: Increased pulsatility of the portal venous waveform with PI of 0.32 in a patient with congestive heart failure.

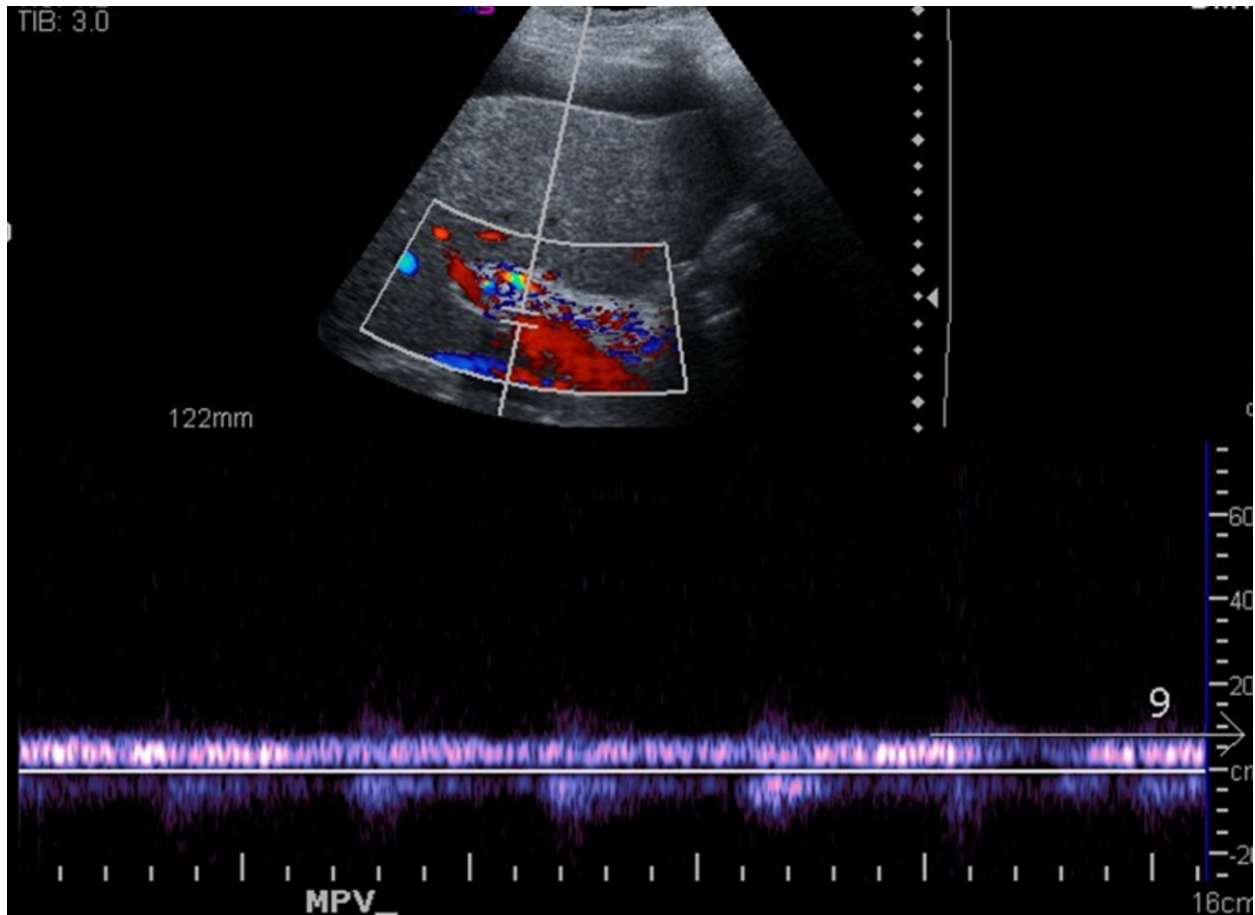


Fig. 6: Sluggish hepatopetal flow in a cirrhotic patient with portal hypertension with flow velocity less than 16 cm/sec.

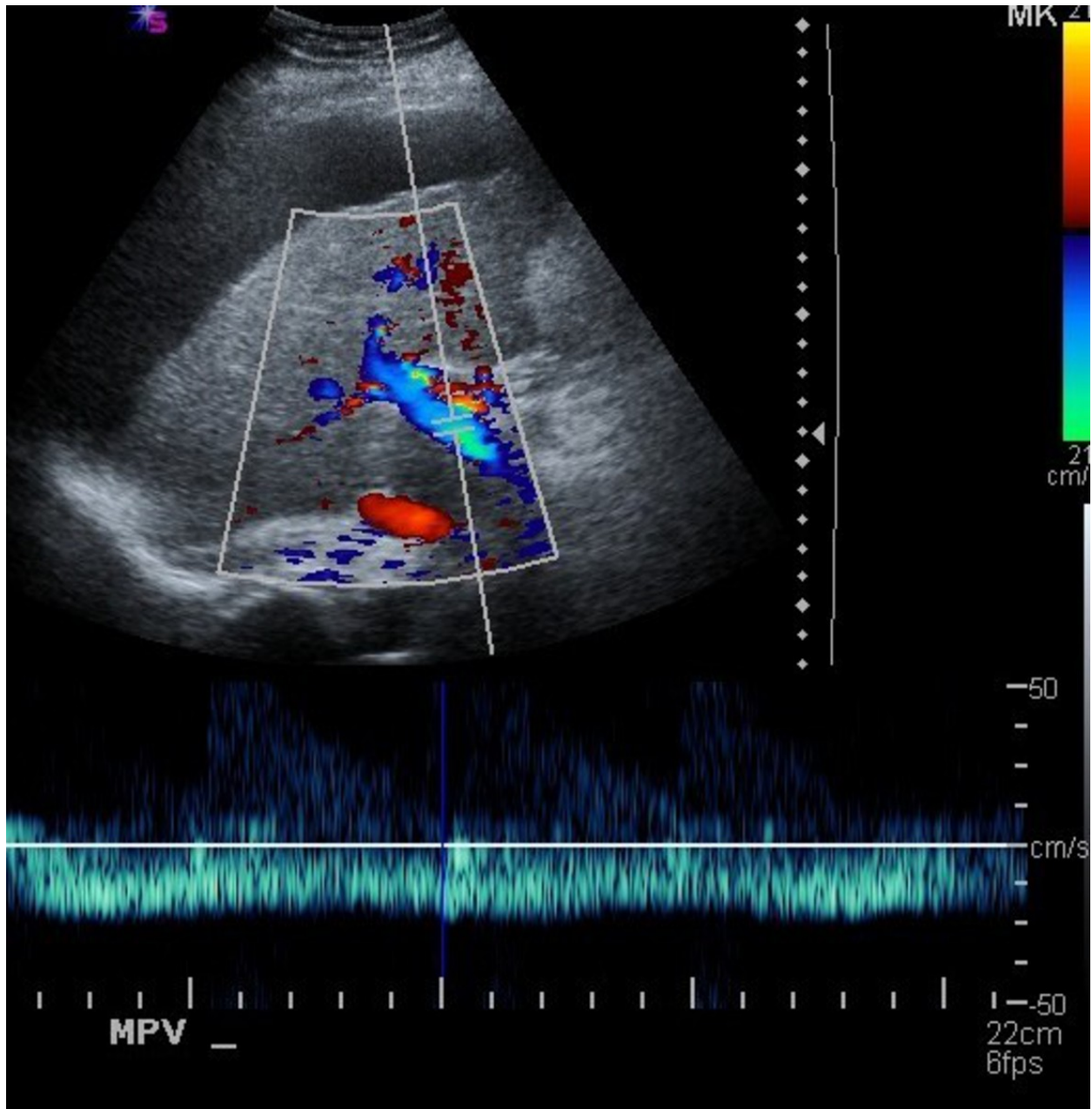


Fig. 7: Hepatofugal flow in main portal vein in a cirrhotic patient with portal hypertension.

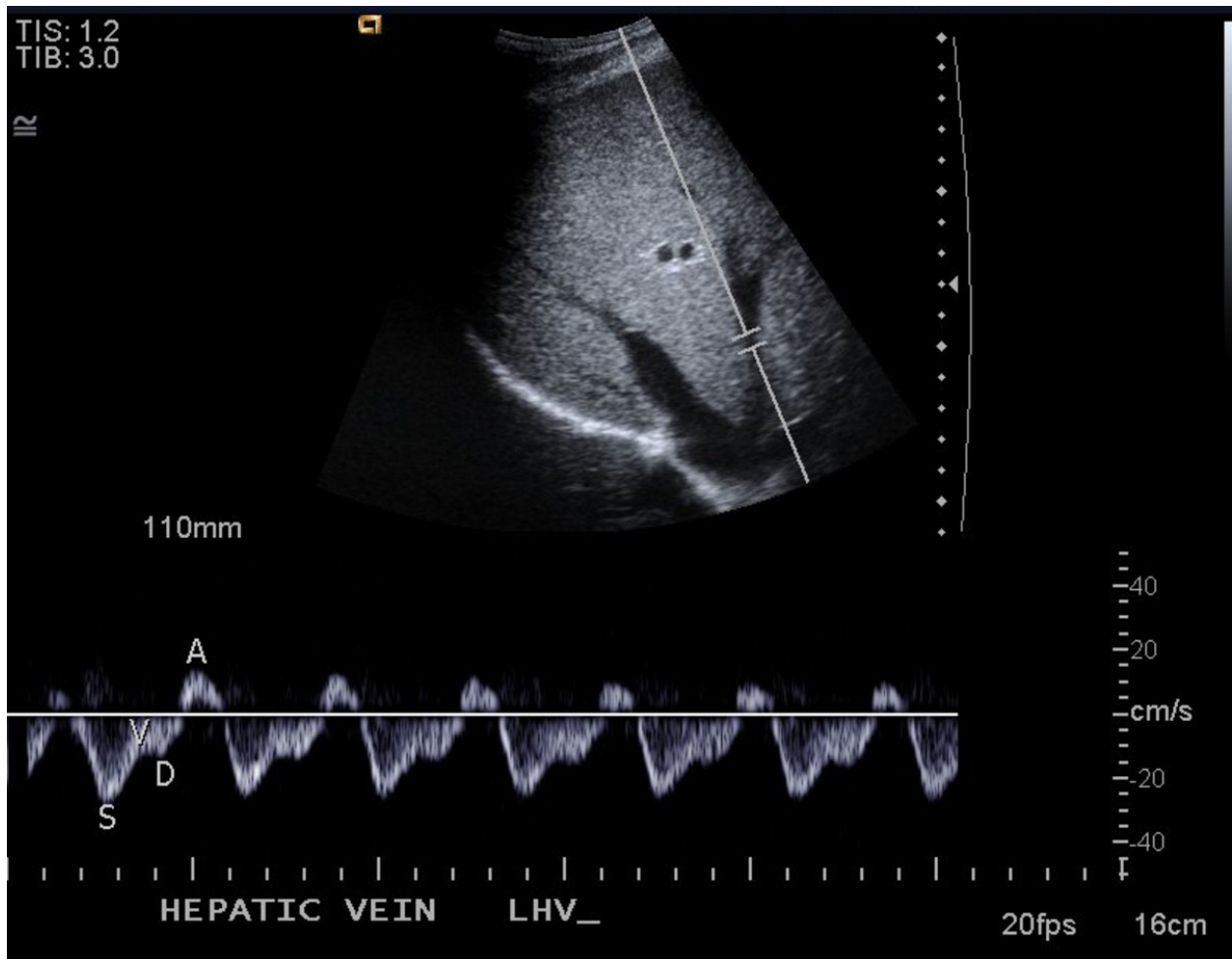


Fig. 8: Normal triphasic hepatic venous flow pattern.

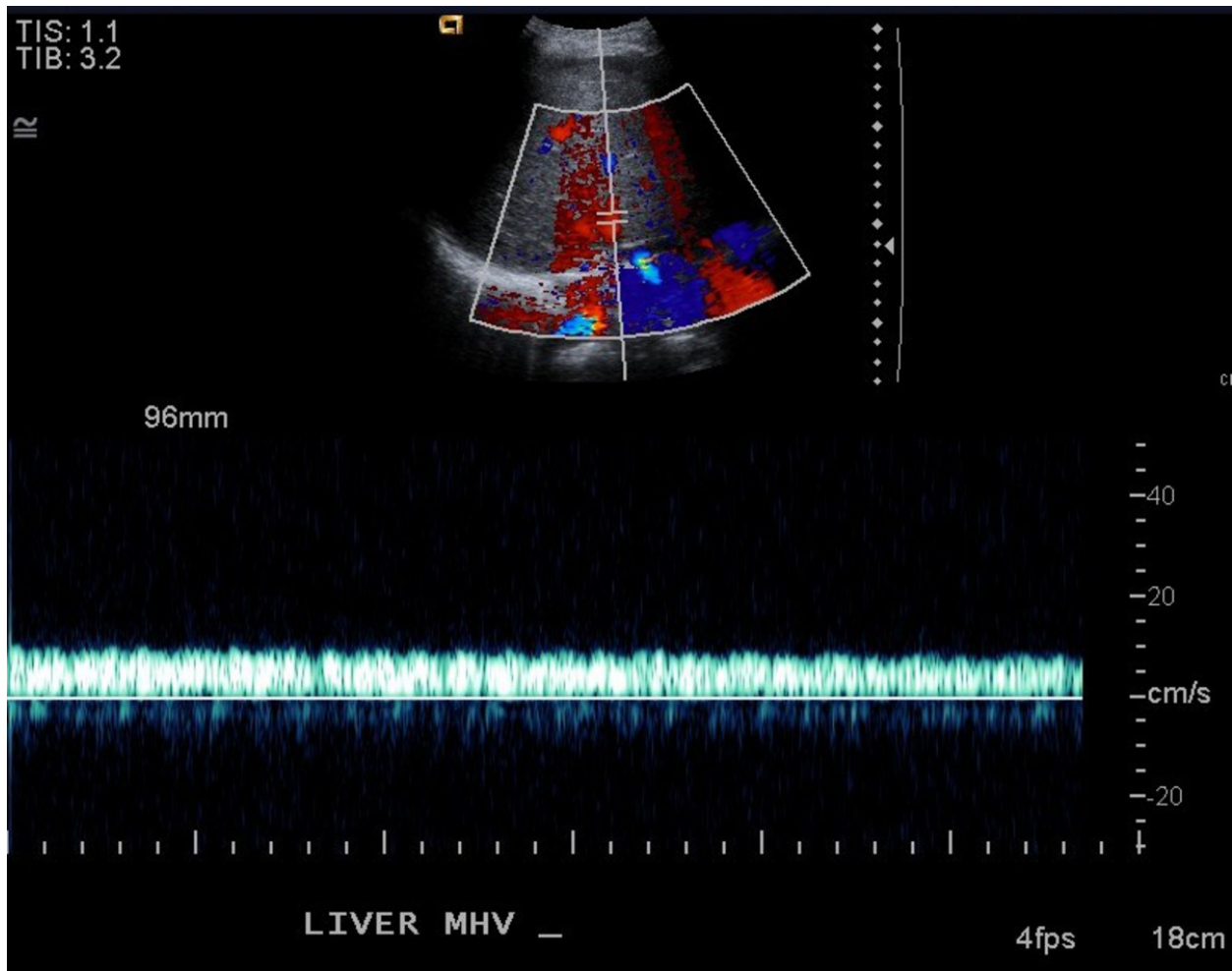


Fig. 9: Complete flow reversal with monophasic waveform in hepatic vein in a patient with chronic occlusion/thrombosis of IVC.

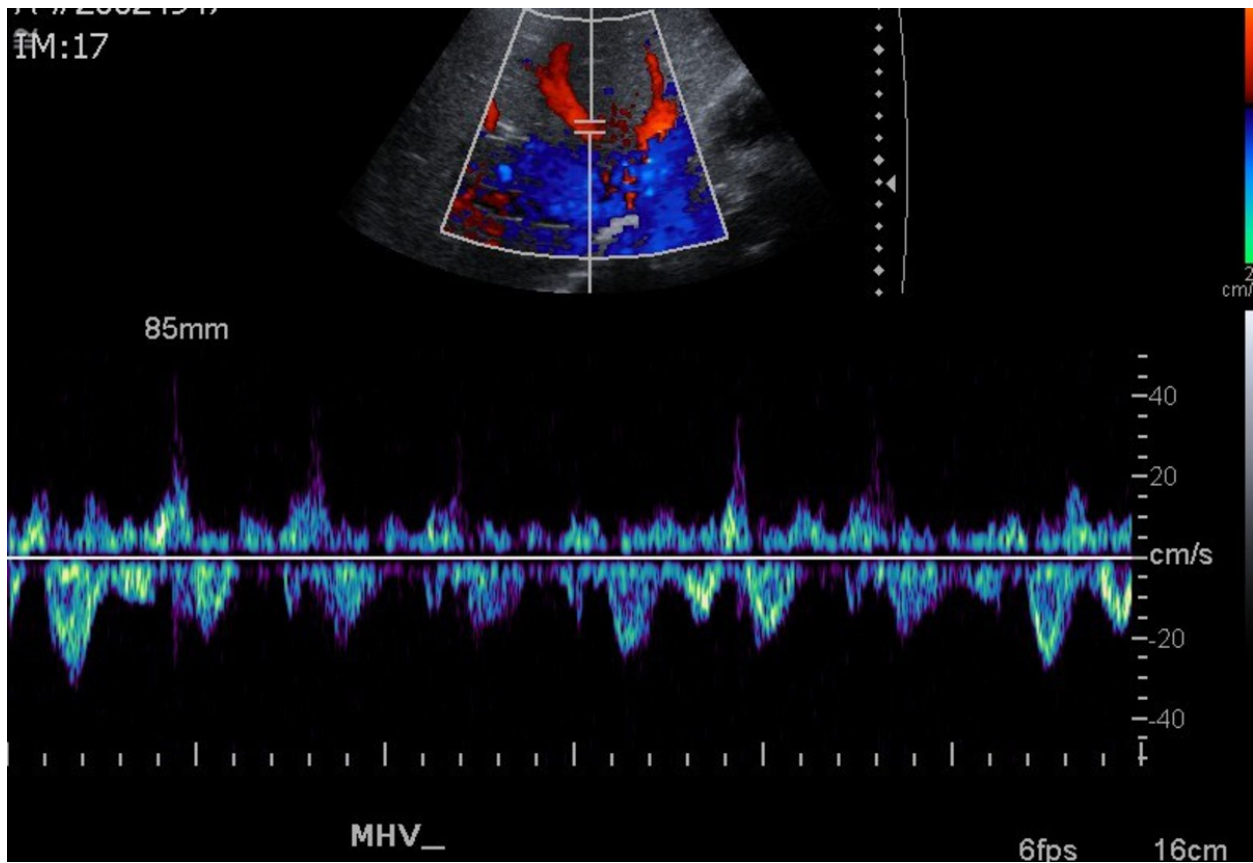


Fig. 10: Irregular Hepatic vein waveform in a sedated intensive care unit patient.

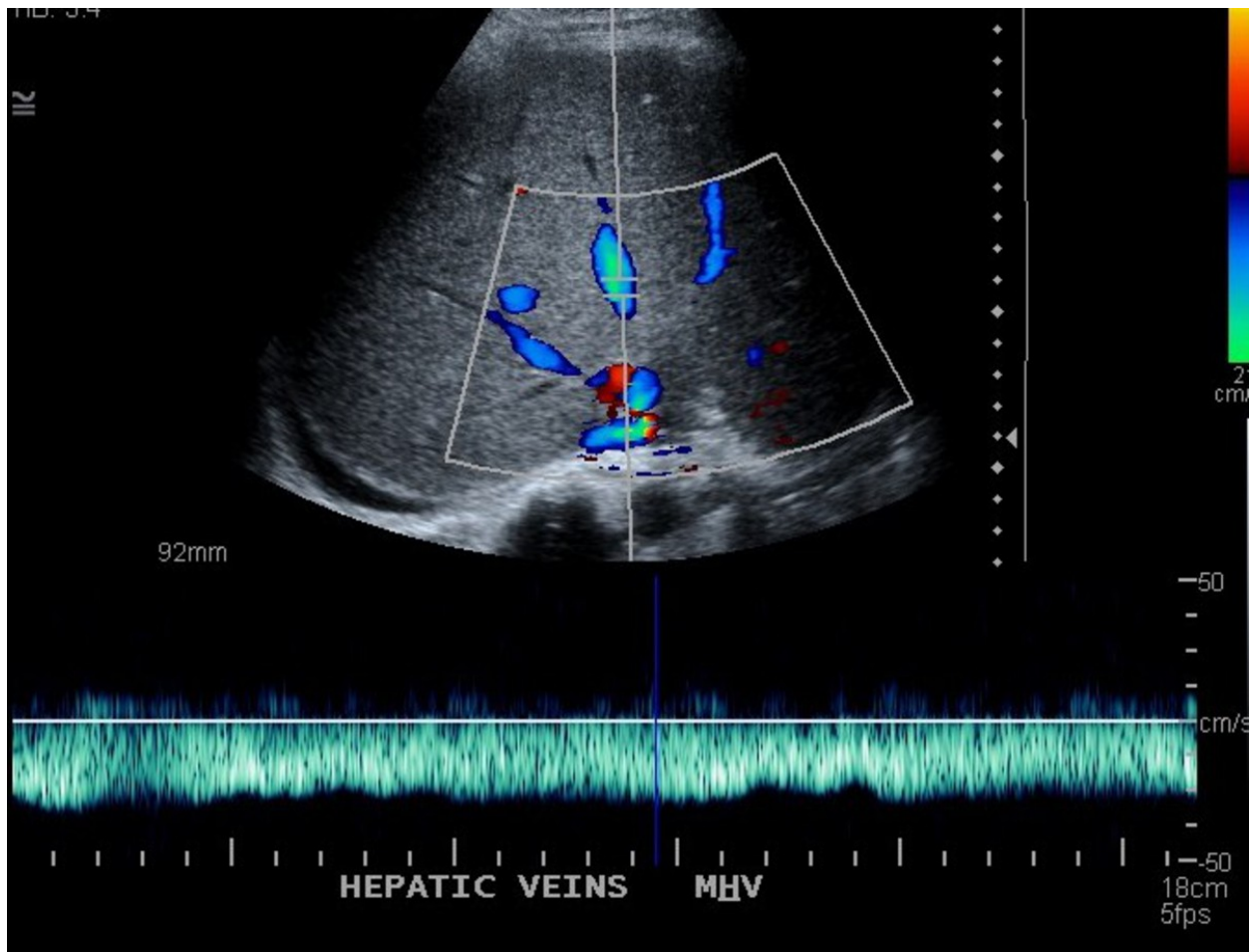


Fig. 11: Blunting of hepatic venous waveform with loss of normal triphasic pattern in a patient with diffuse parenchymal liver disease due to mild cirrhosis and steatosis.

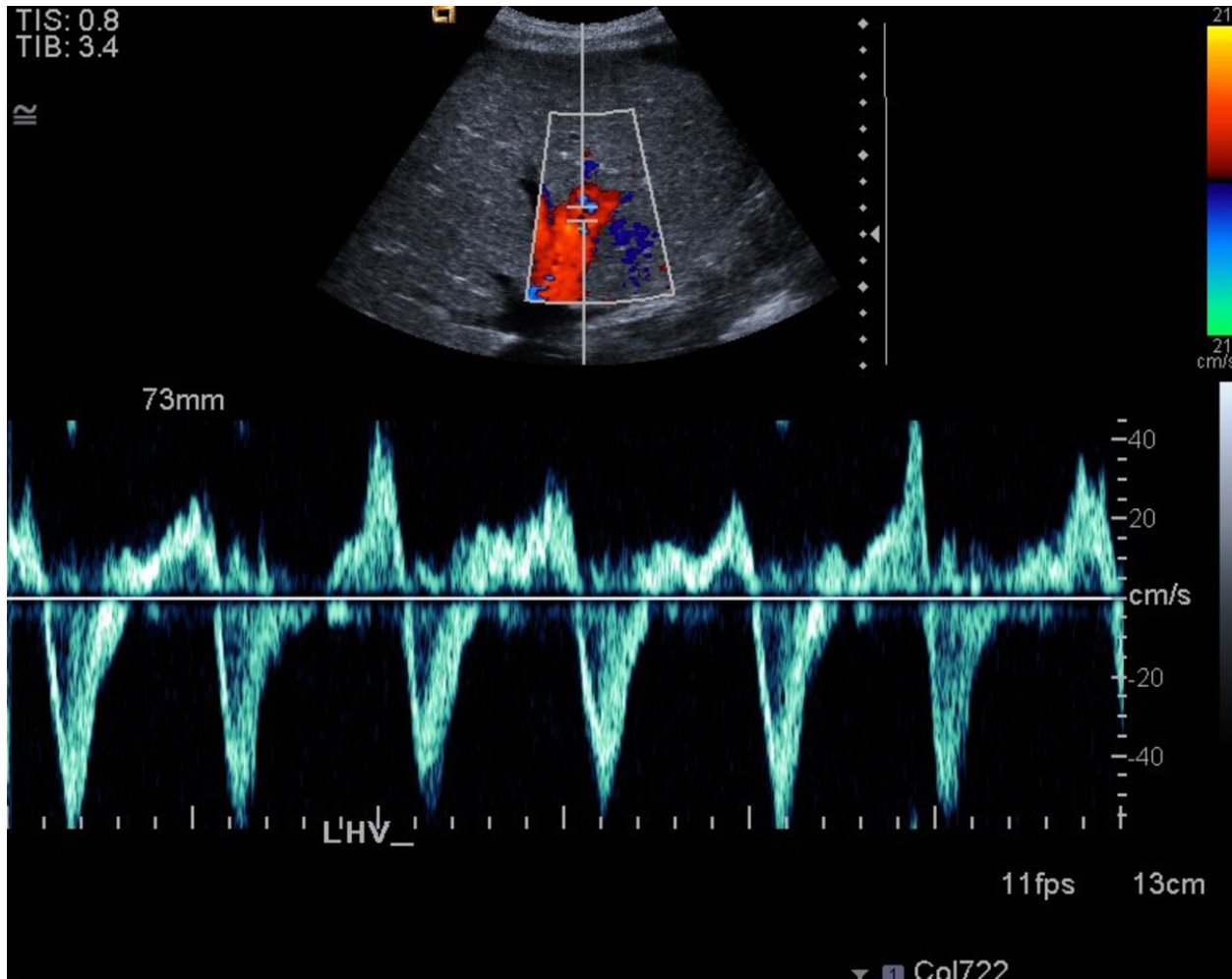


Fig. 12: Biphasic flow pattern in a patient with severe tricuspid regurgitation. Reversal of S wave with formation of a S v complex.

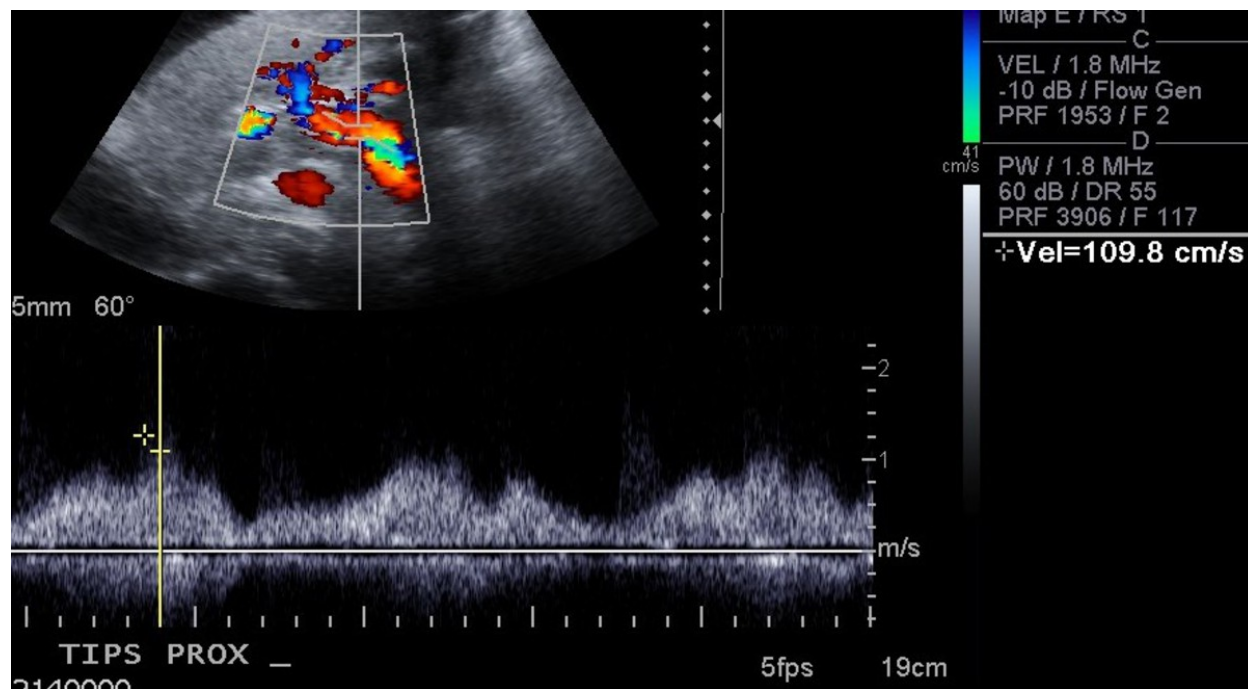


Fig. 13: Flow velocity of 110 cm/sec in TIPS which is within the normal range of 90-190 cm/sec.

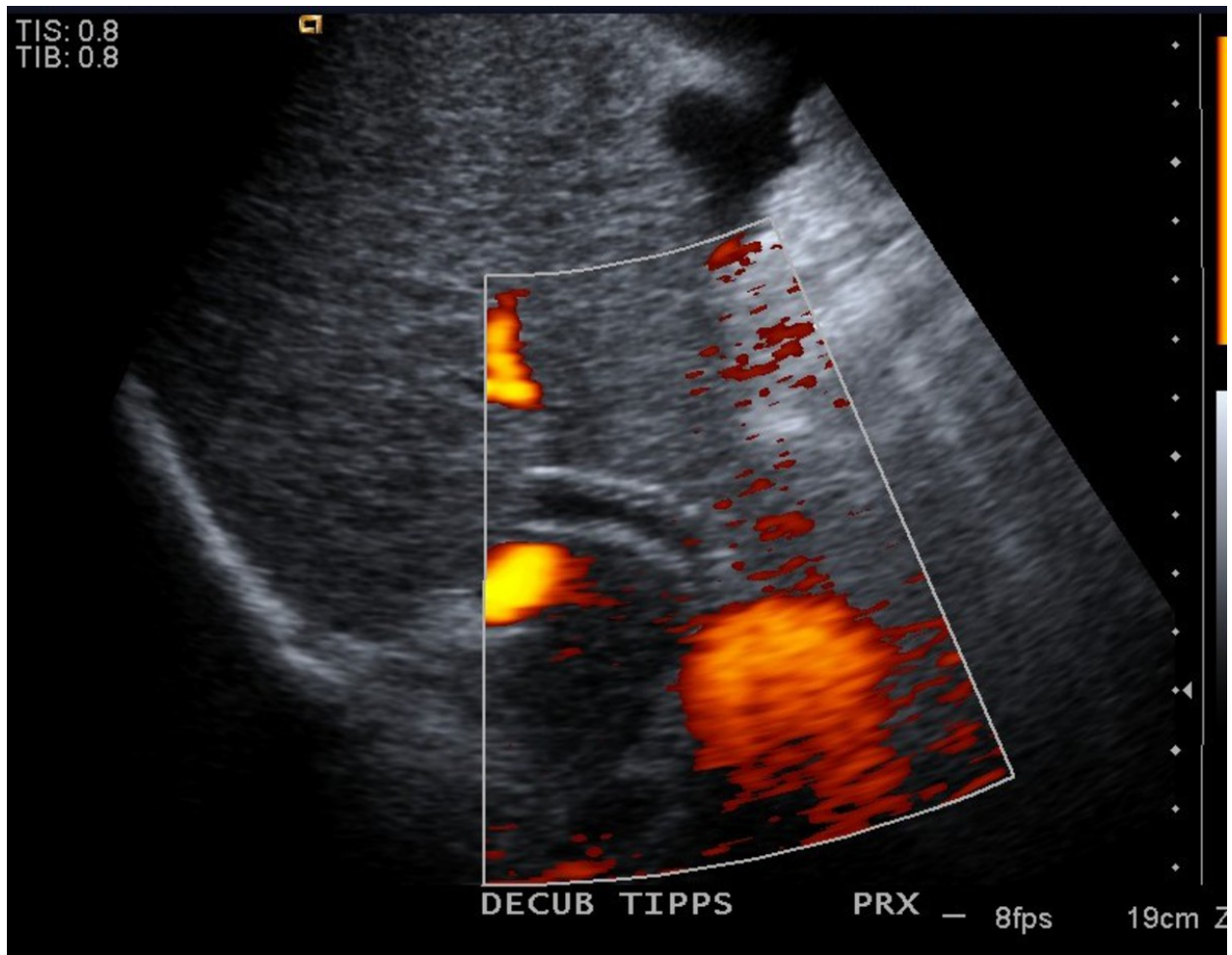


Fig. 14: No Flow noted within the TIPS on power Doppler suggesting complete occlusion.

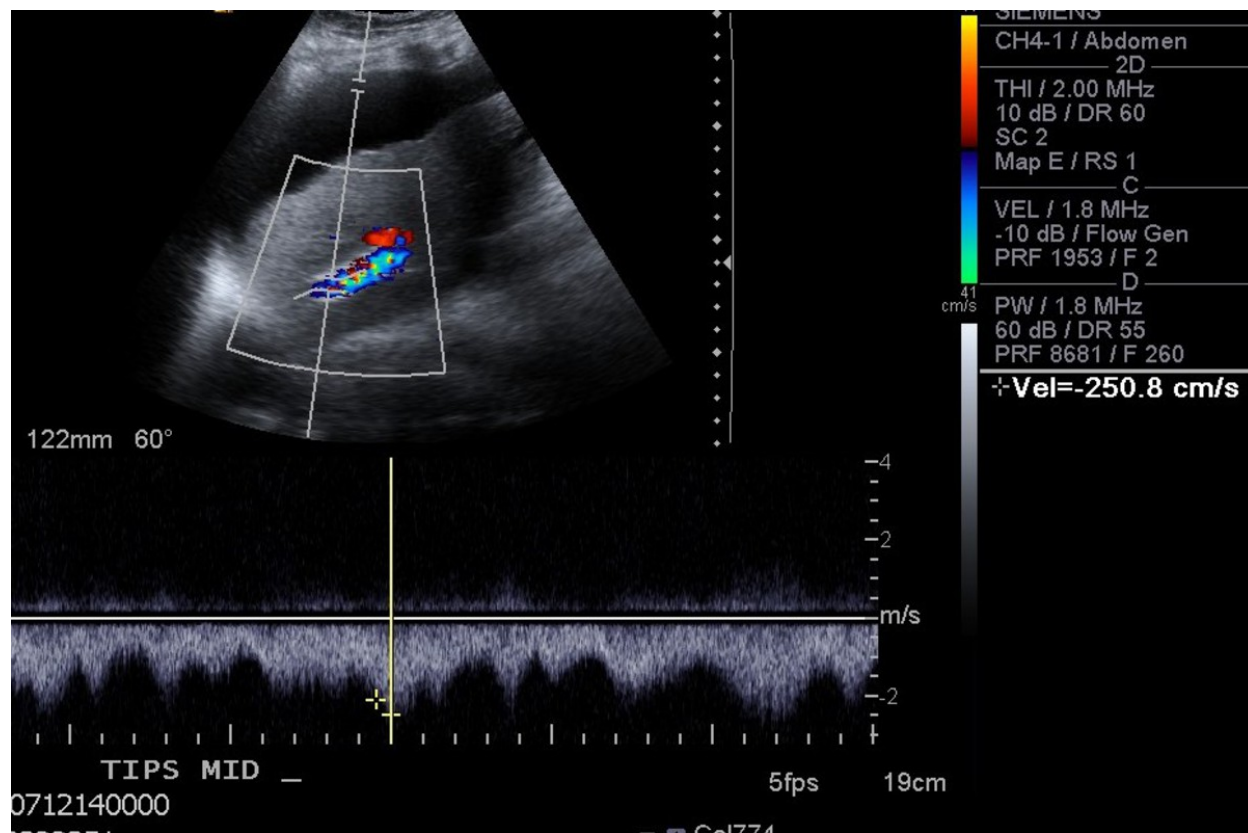


Fig. 15: High flow velocity (250 cm/sec) in the TIPS suggesting shunt malfunction.

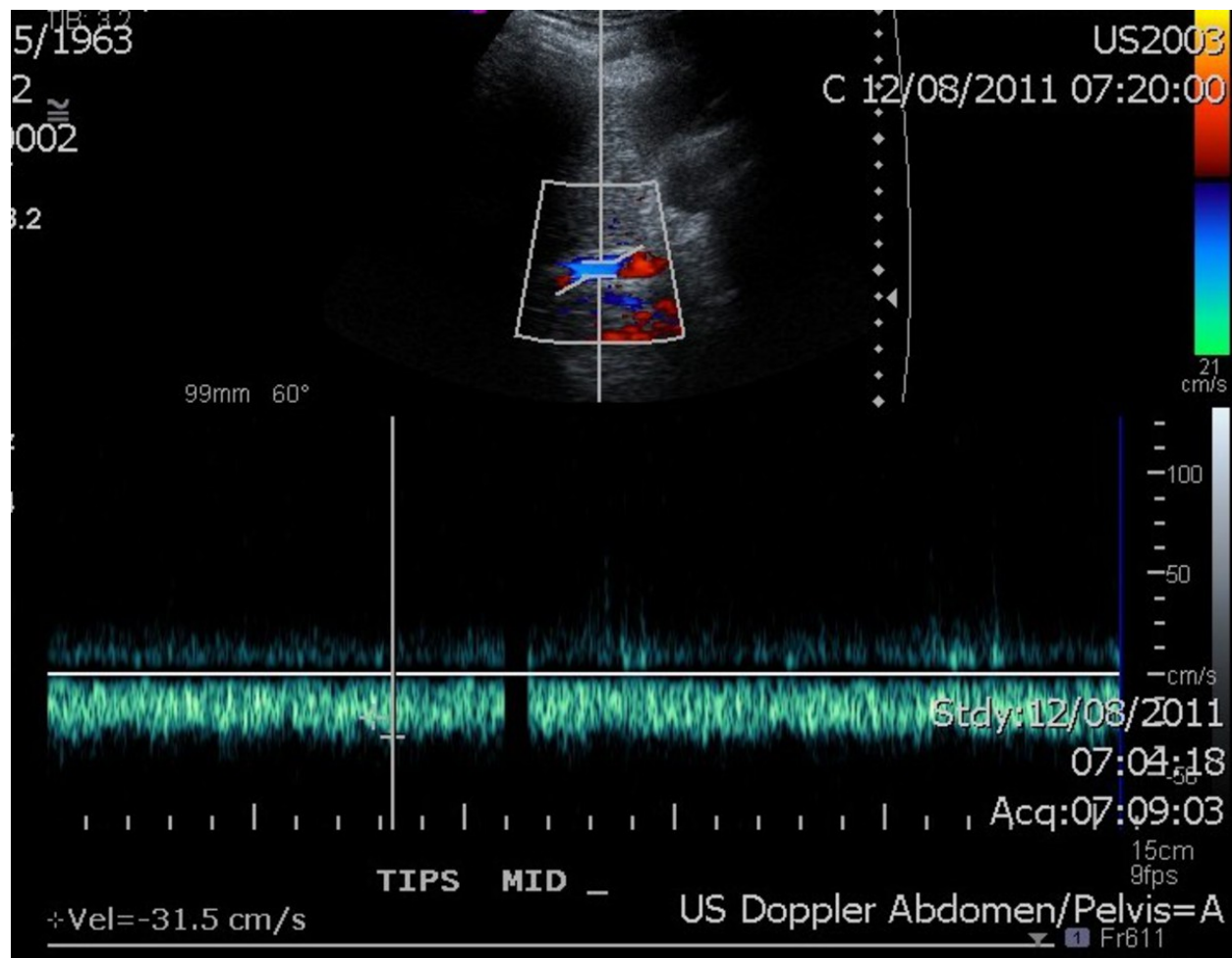


Fig. 16: Low flow velocity(31 cm/sec)in the TIPS suggesting shunt malfunction.

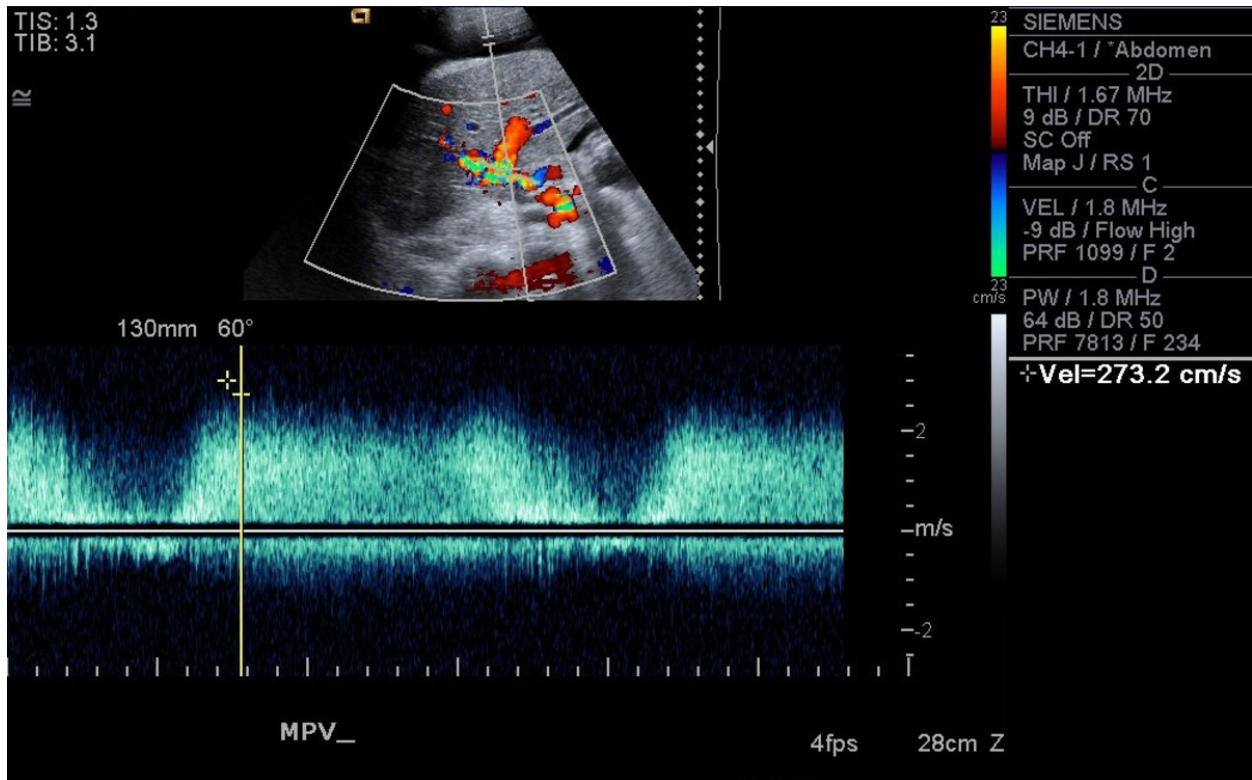


Fig. 17: Significantly high flow velocity at the portal vein anastomotic area in transplanted liver with greater than fivefold velocity in the stenotic segment compared to prestenotic segment compatible with portal vein stenosis.

Imaging findings OR Procedure details

The normal hepatic artery is characterized by pulsatile, low-resistance flow, with abundant antegrade flow in diastole. The flow direction in a normal portal vein is towards the liver, and the Doppler spectrum has continuous, non-pulsatile flow with minor fluctuations. The normal hepatic vein shows a complex triphasic waveform. There are two phases of flow toward the heart and one phase of flow away from the heart. Normal TIPS demonstrates continuous high velocity flow which is minimally pulsatile. Pathological conditions affecting the liver have characteristic effect on blood flow patterns and, therefore, affect the waveforms in the hepatic vessels in a unique way.

Conclusion

Doppler ultrasound provides excellent details of flow patterns in the hepatic vasculature. Proper understanding of the normal waveforms and physiological mechanisms of their generation is important in the interpretation of hepatic Doppler studies. An organized approach will help improve competency in interpreting these studies.

References

Dean AM, Monzer MA. Doppler US of the Liver Made Simple. *RadioGraphics* 2001; 31:161-188.

Meir HS, Ardiana B, Mordecai K. Understanding the Spectral Doppler Waveform of the Hepatic Veins in Health and Disease. *RadioGraphics* 2009; 29: 2081-2098.

Gorg C, riera-Knorrenschild J, Dietrich J. Colour Doppler ultrasound flow patterns in the portal venous system. *British Journal of Radiology* 2002; 75: 919-929.

BARAKAT M. Portal vein pulsatility and spectral width changes in patients with portal hypertension: relation to the severity of liver disease. *The British Journal of Radiology* 2002;75:417-421.

Jane DC, Derek M, Stephanie RW. US of Liver Transplants: Normal and Abnormal. *RadioGraphics* 2003; 23: 1093-1114.

Personal Information